

Nelson, A.J.^{1,5}, Chhem, R.^{1,2}, Cunningham, I.A.^{1,3}, Friedman, S.N.^{1,3}, Garvin, G.⁴, Gibson, G.⁵, Granton, P.V.^{1,3}, Holdsworth, D.W.^{1,3}, Holowka, S.⁶, Longstaffe, F.¹, Lywood, V.⁷, Nguyen, N.¹, Shaw, R.⁵, Trimpour, M.⁵, Wade, A.D.¹, White, C.D.¹

1 - University of Western Ontario; 2 - International Atomic Energy Agency; 3 - Robarts Research Institute; 4 - St. Joseph's Health Care, London; 5 - Royal Ontario Museum; 6 - The Hospital for Sick Children; 7 - John Abbott College

Introduction



The beginnings of the Royal Ontario Museum can be traced back to the excavations and collections of Charles Trick Currelly, a staff member of the Egyptian Exploration Fund in the early 1900s. Currelly excavated with Sir Flinders Petrie at Abydos and with Edouard Naville at Deir el Bahari. With the assistance of Robert Mond and others, Currelly amassed a rich and diverse collection that became the basis for the ROM, which opened its doors in 1914. Part of that collection included several Egyptian mummies (Currelly 1971).



The Egyptological holdings at the ROM include eight mummies: one dating to the Predynastic Period, five from the Pharaonic Period, one from the Roman Period and one without context. Two of these, Nakht and Djedmaatesankh, have been well studied by Peter Lewin and associates, while three more are the subjects of the current investigation. The objectives of this poster are to review the work and accomplishments of the previous research, to describe the preliminary results of the current research project and to outline directions for future work.

Nakht



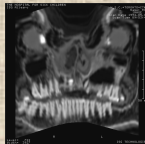Peter Lewin oversaw 20+ years of research focused on this collection of mummies, and accomplished several "firsts" for mummy studies. In 1974 he led the autopsy of Nakht, a mummy with a particularly fine coffin, who dated to the XXIst dynasty. This undertaking was inspired by the autopsy of PUM-II (Lewin 1977), performed in 1973 by A. Cockburn and the Paleopathology Association (Cockburn et al. 1998).

Nakht's autopsy brought together a diverse and talented group of medical and Egyptological researchers who found that: Nakht was an adolescent male who had suffered from episodes of childhood stress, had granite particles in his lungs, schistosoma and tapeworm cysts in several organs and cirrhosis of the liver, probably secondary to the parasite infestation. They also noted that he had been given a very cursory embalming without the use of natron, all his organs (including his brain) were *in situ*, and the body had apparently been wrapped before it had fully desiccated. These results shed new light on the life and afterlife of a poor weaver who had served in the temple of User-khau-re (see Hart et al. 1977a and accompanying papers).

Firsts



Lewin & Harwood Nash (1977) were the first researchers to use the then new technology of Computerized Axial Tomography (CT) to look at the internal structure of mummified tissue when they analyzed Nakht's brain. At that time, CT body scanners had only been in hospitals in North America for about 2 years. The XXIst Dynasty Mummy Djedmaatesankh, was the first whole mummy to be scanned, once in 1977 (Lewin 1978), then again in 1994 at the Hospital for Sick Children (Melcher et al. 1997). Later, researchers at the Hospital for Sick Children in Toronto were the first to use newly developed software to produce 3-dimensional images from the CT slices (Lewin 1987) – of a mummified head and a cat. Thus, this research has been on the cutting edge of new technological developments in medical imaging.



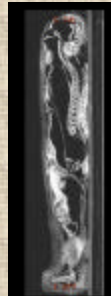Current Research



In 2007, mummy research on ROM mummies moved into a new phase, with the beginning of a collaborative project involving the ROM and The University of Western Ontario. The purpose of the new project is to build on the work already done by including 3 new mummies, to construct osteobiographies for these 3 individuals and to bring new developments in imaging physics to bear on mummy studies. Some of the preliminary results of this work are presented here.

The three mummies chosen for this project are ROM 910.5.3, a XXIst dynasty individual with a coffin indicating that it belonged to a low-ranking priest known as a "wab priest". The second is ROM 910.13, a Roman period infant with an exquisite painted textile. The third is an uncontexted infant mummy. These mummies were CT scanned at London Health Sciences Centre on 3 separate occasions during 2007/2008. In addition, digital x-rays were taken of the infant mummies.

ROM 910.5.3




Our first surprise was that the mummy 910.5.3 was not a male, as the coffin text would suggest; instead, "he" is a she! Like Nakht, her embalming was not of high quality. She was eviscerated through her perineum, all internal organs as far as the tongue were removed and her brain was left in place. The retraction of the skin from the wrappings indicated that she had not been fully desiccated when she was wrapped. There is extensive damage to the tissue around the throat and lower back, accompanied by evidence for insect activity. No amulets or other offerings were noted in her wrappings.

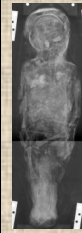This pattern of preparation of the body is roughly consistent with Herodotus' description of methods performed for those who "wished to avoid expense" or were of "poorer classes". In his description, cedar oil (or similar corrosive fluid) was introduced into the abdomen to dissolve and wash out the organs (see Rawlinson 1859). However, he also suggested that these mummies were then treated in natron for 70 days, which does not appear to have been the case here.

We estimated the age of this individual to be in her 20s, as her 3rd molars had erupted and are in position to be in occlusion, the basi-sphenoid suture and medial clavicles are fused and her skeleton does not demonstrate evidence of advanced wear and tear. The only pathological condition noted was the impaction of her lower 3rd molars and unilateral sacro-iliitis.

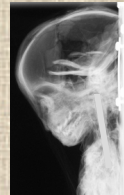We segmented the skull from the CT scans, created a 3D print and a facial reconstruction was undertaken by Victoria Lywood.



The "Babies"



Both the infants were determined to be very young. The unnumbered individual was approximately 9 months old, while 910.13 was less than 6 months old. The internal organs of both mummies appear to have been removed. The bones of 910.13 are out of order, a condition found in other mummies that suggests that the mummy was violently disturbed when its joints were brittle after it was desiccated. The unnumbered individual has a piece of wood that was introduced into the thorax and passed through the base of the skull that functioned to keep the skull in position.



Ongoing Research

What began 30+ years ago as a collaborative, multidisciplinary project focused on a mummy autopsy has now shifted to be a collaborative, multidisciplinary project focused on minimally invasive methods of obtaining information from these valuable specimens. As such, this project represents the development of the field of mummy studies, and the move toward the use of techniques designed to maximize the recovery of information while minimizing the impact on the mummies, in order to preserve them for future generations.

Ongoing projects include:

- isotopic analysis of a small sample of exposed hair of 910.5.3: $\delta^{13}C = -20.3$, $\delta^{14}N = 14.6$. These figures are consistent with a C3 diet (wheat, barley, fruits, vegetables) and with an origin in a Nile Valley site.

- magnetic resonance scan of Nakht's brain. Nakht's brain did not desiccate completely, rather it is saponified. This MR scan with spectroscopic analysis of an Egyptian mummy's brain is another first (Karlik et al. 2007).

- virtual animation – we have prepared an animation based on the CT scan data of 910.5.3. The animation will feature in a video, as part of the Canadian Museum of Civilization's exhibit "Tombs of Eternity - The Afterlife in Ancient Egypt" (Dec. 19, 2008 – Aug. 16, 2009, Ottawa, Canada).

- dual energy scans – we are working to apply methods developed in medical and small animal imaging to automate segmentation on the basis of repeat scans at different energy levels. This technique has great promise for mummy studies in general (Friedman et al. 2009).

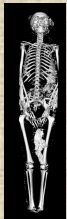- identification of wood – we are investigating the possibility of identifying wood at the species level on the basis of its CT characteristics. This would allow us to identify the wood used in the unnumbered individuals as well as other artifacts enclosed in wrappings or coffins.

- optimization of image quality by minimizing signal to noise ratios.

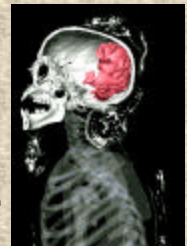

Cross section of a wooden coffin, showing the less dense coffin wood (probably sycamore-fig) and a more dense plug (probably tamarisk), with a dense layer underlying surface painting

- we hope to use these studies to form the basis of a collaborative mummy database, based on GE's internet based Picture Archive Communication System (application in to CFI).



Dual energy segmentation



Screen shot of animation

Citation

Nelson, A.J., Chhem, R., Cunningham, I.A., Friedman, S.N., Garvin, G., Gibson, G., Granton, P.V., Holdsworth, D.W., Holowka, S. Longstaffe, F., Lywood, V., Nguyen, N., Shaw, R., Trumpour, M., Wade, A.D., White, C.D. 2009. The ROM/ UWO Mummy Project: Amicrocosm of progress in mummy research. Poster Presented to the 1st Bolzano Congress on Mummy Studies, Bolzano Italy, March 18-21, 2009.

Literature Cited

- Barraco, R.A. 1977. Analysis of protein extract. Canadian Medical Association Journal 117: 474.
- de Boni, U., Lenczner, M.M. & Scott, J.W. 1977. *Trichinella spiralis* cyst. Canadian Medical Association Journal 117: 472.
- Cockburn, A., Barraco, R.A., Peck, W.H. & Reyman, T.A. 1998. A classic mummy: PUM-II. In: A. Cockburn, E. Cockburn & T.A. Reyman eds, Mummies, Disease and Ancient Cultures (second edition), pp: 69-90. Cambridge University Press: Cambridge.
- Currelly, Charles Trick. 1971. I Brought the Ages Home. Royal Ontario Museum: Toronto.
- Friedman, S.N., Nelson, A.J., Granton, P.V., Holdsworth, D.W., Chhem, R. & Cunningham, I.A. 2009. Dual-energy computed automated bone identification in ancient Egyptian mummies. Paper presented to the Paper Presented to the 1st Bolzano Congress on Mummy Studies, Bolzano Italy, March 20, 2009.
- Hart, G.D., Cockburn, A., Millet, N.B. & Scott, J.W. 1977a. Lessons learned from the autopsy of an Egyptian mummy. Canadian Medical Association Journal 117: 415-416.
- Hart, G.D., Kvas, I & Soots, M.L. 1977b. Blood group testing. Canadian Medical Association Journal 117: 476.
- Horne, P.D. & Lewin, P.K. 1977. Electron microscopy of mummified tissue. Canadian Medical Association Journal 117: 472-473.
- Karlik, S.J., Bartha, R. Kennedy, K. & Chhem, R. 2007. MRI and multinuclear MR spectroscopy of a 3,200-year-old Egyptian mummy brain. American Journal of Radiology 189: W105-W110.
- Lewin, P.K. 1977. Mummies that I have known. American Journal of Diseases of Children 131(3): 349-350.
- Lewin, P.K. 1978. Whole body CT scan of an Egyptian mummy (abstract). Paleopathology Association Newsletter, Apr 1978: T7-T8.
- Lewin, P.K. 1987. Stereoscan imaging from composite 'CAT' scans (abstract). Paleopathology Association Newsletter, June 1987: 17.
- Lewin, P.K. & Harwood-Nash, D.C. 1977. X-ray computed axial tomography of an ancient Egyptian brain. International Research Communication System, Medical Sciences 5: 78.
- Lynn, G.E. & Benitez, J.T. 1977. Examination of ears. Canadian Medical Association Journal 117: 469.
- Melcher, A.H., Howloka, S. Pharoah, M. & Lewin, P. 1997. Non-invasive computer tomography and three-dimensional reconstruction of the dentition of a 2,800-year-old Egyptian mummy exhibiting extensive dental disease. American Journal of Physical Anthropology 103: 329-340.
- Millett, N.B. 1977. Archaeologic background. Canadian Medical Association Journal 117: 462.
- Rawlinson, G. (translator) 1859. The History of Herodotus. D. Appleton & Company: New York
- Rideout, D.F. 1977. Radiologic examination. Canadian Medical Association Journal 117: 463.
- Reyman, T.A., Zimmerman, M.R. & Lewin, P.K. 1977. Histopathologic investigation. Canadian Medical Association Journal 117: 470-472
- Scott, J.W., Horne, P.D., Hart, G.D. & Savage, H. 1977. Gross anatomic and miscellaneous studies. Canadian Medical Association Journal 117: 464-469.

Acknowledgements

Current research:

Core funding for this project was provided by Dr. Brian Timney (Dean of Social Science, University of Western Ontario), Dr. Carol Herbert (Schulich School of Medicine, UWO) and Dr. Ted Hewitt, Vice-President Research (UWO). Scan time was generously donated by the London Health Sciences Centre. The Northern Casket Company (Lindsay, ON) kindly provided the shipping crates for the mummies. Additional funds were provided by the lead author's Faculty Scholar Grant and from the Department of Anthropology's mummy outreach program.

In addition, we would like to acknowledge:

- from the Royal Ontario Museum: Cathy Stewart and the staff of the conservation department, Nur Bahal and Krzysztof Grzymiski.
- from the London Health Sciences Centre: Gordon Allan, Douglas Brunton, Mary Castle, Eadie Deaville, Paul Howarth, Sheila MacDonald, Barb Mylemans, C. Romagnoli, Barb Smith and Trevor Szekeres.
- from UWO – Tim Wilson.
- from John Abbott College – M. Ewanchyna.
- the Department of Anthropology, UWO.